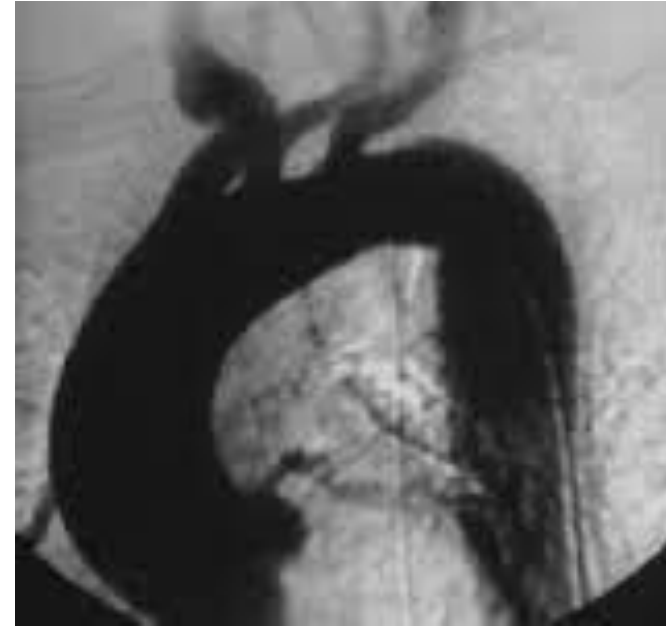


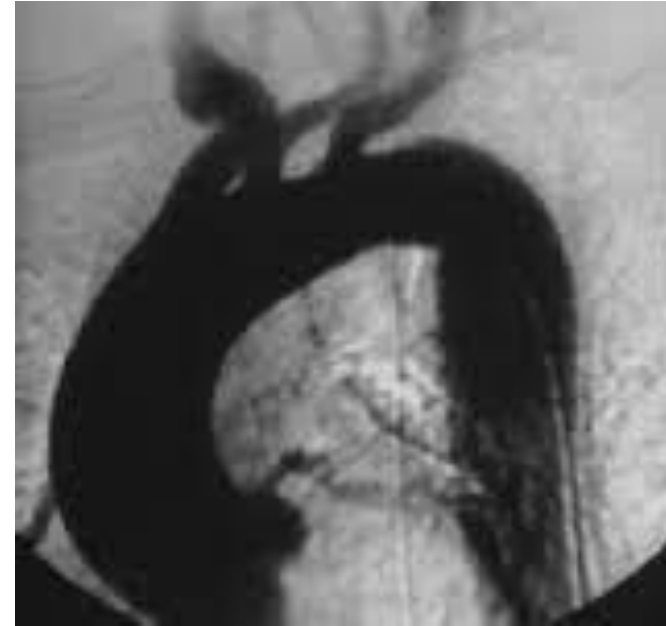
# Question 19

- Which of the following best describes the arch angiogram?
  - A. Right-sided aortic arch
  - B. Retroesophageal right subclavian artery
  - C. Bovine arch
  - D. Anomalous left vertebral artery
  - E. Normal aortic arch

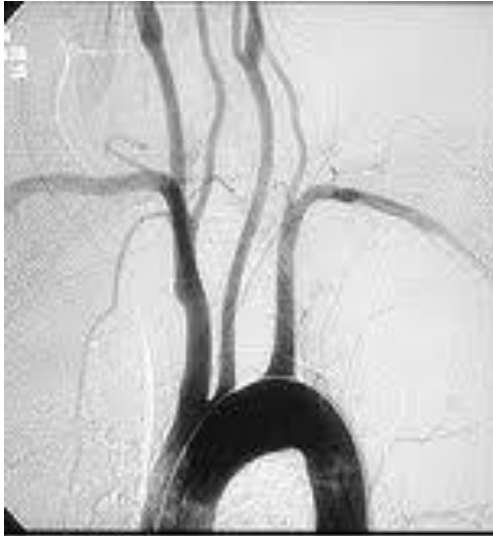

# Question 19

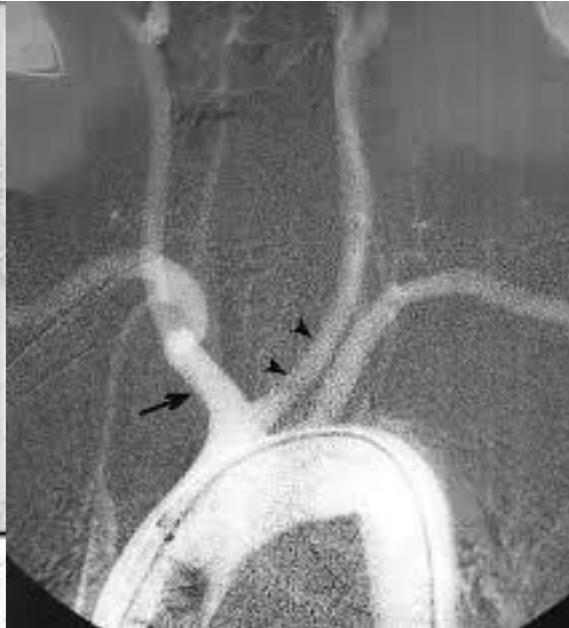- Which of the following best describes the arch angiogram?
  - A. Right-sided aortic arch
  - B. Retroesophageal right subclavian artery
  - C. Bovine arch
  - D. Anomalous left vertebral artery
  - E. Normal aortic arch



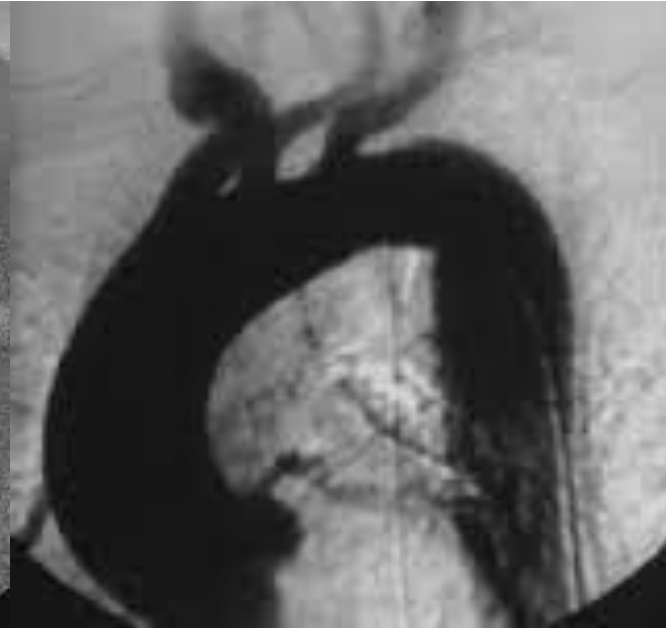
# Question 19



Normal



Bovine arch



Right-sided aortic arch